

Management of Coats' Disease in the Pediatric Ophthalmology Department, Ibn Rochd University Hospital, Casablanca

Soukaina Bouziane, Asmaa ElKettani, Loubna Elmaaloum, Bouchra Allali, Khalid Zaghoul

20 Août Hospital, Pediatric Ophthalmology Department, Ibn Rochd University Hospital, Casablanca

Corresponding author :

S.Bouziane

6 Rue Lahcen Al Aarjoune, Casablanca 20250

Received 20 July 2021; Accepted 5 August 2021

Abstract

Methods: This retrospective study illustrates the management of Coats disease in the pediatric ophthalmology department in Ibn Rochd University Hospital of Casablanca during the period November 2009- November 2020, inclusive.

Results : Our study involved 15 patients (16 eyes), all of them were boys. Mean age at presentation was 3 years. The diagnosis delay varied from 0 to 3 years with an average of 11 months. Strabismus and leukocoria was the main reason for consultation.

At initial presentation, disease severity was variable with a predominance of stage 4. Ultrasound was performed in all patients.

Retinal angiography was performed in 6 patients to confirm the diagnosis, guide the treatment, check its effectiveness and to indicate a possible therapeutic complement.

Angiography showed rubeosis in a case of neovascular glaucoma. All patients benefited from MRI or CT-scan. Concerning the treatment, laser photocoagulation was performed on 8 eyes. All of them presented a Coats disease stage 2B or 3. In 5 cases, it was associated with cryoapplication. Three patients received an intravitreal injection of anti-VEGF, bevacizumab. Enucleation was performed for two patients.

For 4 eyes presenting a total retinal detachment with glaucoma or a cataract with retinal detachment, therapeutic abstention was indicated.

Conclusion: The severity of Coats disease is variable. The prognosis depends on the speed of setting up a complete treatment to eliminate the vascular anomalies and to avoid their complications.

Keywords : Coats Disease, Retinal Telangiectasis, laser photocoagulation, cryotherapy.

I. BACKGROUND :

Coats disease is a rare pathology. Very few case series have been studied in Africa. The main objective of our study was to share the experience of the pediatric ophthalmology department of Casablanca, regarding the epidemiology, clinical and treatment of this pathology. We aimed to compare our data to those of the international literature, understand failures, improve the management of this pathology in our service and allow other African countries to compare and improve the quality of care and to be able to offer patients suffering from Coats disease the hope of keeping their eyesight.

What is already known on this topic:

- Clinical manifestations of Coats disease
- The place of laser photocoagulation as a main treatment that targets peripheral vascular abnormalities as well as capillary non-perfusion areas visualized by fluorescein angiography
- The role of anti-VEGF and cryotherapy in the treatment of Coats' disease

What this study adds:

- This study is interested in the particularities of Coats disease in Morocco.
- It is a series that reports a significant number of cases

We have no competing interests

Introduction

Coats' disease is an infrequent retinal angiomasia affecting mainly the male child. It's usually unilateral. It combines telangiectasia and exudative retinopathy.

With an unknown physiopathology, it is thought to be caused by a primitive endothelial abnormality disrupting the development of retinal capillaries [1]

This disease mimics retinoblastoma, making it the main differential diagnosis. Often isolated, Coats' disease can nevertheless be associated with other systemic disorders. This is called Coats' plus syndrome.

This retrospective study aims to illustrate the management of this pathology in the pediatric ophthalmology department in Ibn Rochd University Hospital of Casablanca.

Patients and methods:

Our study is retrospective. It includes all children under the age of 16, followed for a Coats' disease in the pediatric ophthalmology department of Ibn Rochd University Hospital of Casablanca during the period November 2009- November 2018, inclusive.

The diagnosis was based on fundus examination under general anesthesia with retinophotography by Retcam and angiography if necessary. We looked for anomalies corresponding to the conventional international criteria [2], including subretinal exudates that may progress to the macula, telangiectasia, intraretinal edema around angiomasia lesions, light-bulb microaneurysms and tortuous vessels, intraretinal haemorrhage, retrohyaloid hematomas or intravitreal hemorrhages.

The following parameters were collected from the medical records: age, sex, reason of consultation, consultation time, fundus examination, Shields classification [2], paraclinical tests and their results, treatment and finally the evolution.

Results:

Epidemiology:

Our study involved 15 patients (16 eyes), all of them were boys. Mean age at presentation was 3 years (range 6 months- 5 years and 6 months).

In our series, Coats' disease was unilateral in 14 cases and bilateral in 1 case.

The diagnosis delay varied from 0 to 3 years with an average of 11 months. There were no similar cases in our patients' families.

Clinical diagnosis:

Strabismus was the main reason for consultation for 53% of patients.

Leukocoria pushed to consultation in 47% of children.

Two children showed a decrease in visual acuity.

Initial visual acuity was unquantifiable for 9 patients. One child did not perceive light in the affected eye. Three children had a light perception. One could count fingers closely. One patient had a visual acuity at 1/10.

Eye fundus:

At the eye fundus, we observed telangiectasia with multiple sub-retinal exudates with imprecise yellowish in 100% of patients (Fig1)

We classified the lesions according to Shields classification (Fig2) [Table I].

At initial presentation, disease severity was variable with a predominance of stage 4.

Paraclinical examinations:

Ultrasound:

Ultrasound was performed in all patients. It showed highlight masses close of the posterior pole. A hypervascularized retinal detachment was noted in 7 patients.

Fluorescein angiography:

Retinal angiography was performed in 6 patients.

The interest was to establish a diagnosis

for three of the patients. This revealed telangiectasia already visible at the fundus, bulb-like hyperfluorescence and avascular regions in the early phase with diffuse hyperfluorescence due to leakage of telangiectatic vascularization in the late phase (Fig 3) . For these patients, angiography guided the treatment.

For two patients, angiography was performed to evaluate the efficacy of laser photocoagulation treatment.

Complementary treatment was performed after angiography for these patients. Angiography showed rubeosis in a case of neovascular glaucoma (Fig 4)

CT or MRI:

The main objective of these paraclinical tests is to rule out the main differential diagnosis, retinoblastoma.

All patients benefited from these examinations.

MRI with analysis of T1, T2 and T1 sequences with gadolinium injection was indicated as first line. It was performed for 9 patients. It showed a hyper-intense image in T1 and in T2 without contrast enhancement to gadolinium.

The CT scan was only indicated when MRI was not possible to perform.

Treatment:

Laser photocoagulation was performed on 8 eyes. All of them presented a coats disease stage 2B or 3. Five of them benefited from a cryoapplication.

Laser photocoagulation targeted peripheral vascular abnormalities seen on retinography as well as non-perfusion capillary areas visualized on fluorescein angiography.

The laser used was a diode laser (Iridex) 810 nm.

The number of sessions was 1 to 5 with a required number of spots from 250 to 500 impacts per session and the power required to achieve bleaching of lesions.

Concerning cryoapplication, 1 to 3 sessions were performed, for 5 patients followed by photocoagulation treatment.

Three patients with an exudative subtotal retinal detachment received an intravitreal injection of anti-VEGF, bevacizumab. The number of injections was on average 5.

One of whom also received a subretinal fluid drainage.

Enucleation was performed for two patients. One of them presented, despite the completion of all additional tests, a difficulty in formally eliminating the diagnosis of retinoblastoma. The other had a stage 4 complicated with a painful glaucoma resistant to treatment.

Regarding the 2 enucleated eyes, the pathological anatomy concluded to a Coats disease.

Therapeutic abstention was indicated for 4 eyes. Two of them presented a total retinal detachment with glaucoma. Two others presented cataracts with retinal detachment.

Evolution:

For 3 patients with Coats' disease at stage 2B, there was an almost complete resorption of exudation with average visual acuity at 3/10 (Fig5)

For patients with Coats' disease at stage 3, the presence of massive macular retinal exudation has lowered the visual prognosis with the presence after treatment of sequelary macular fibrosis. Average visual acuity was at counting fingers closely.

For patients with stages 4 and 5, there was no significant improvement in visual acuity.

II. DISCUSSION :

Our study describes a series of cases of Coats' disease. Epidemiological and demographic data are consistent with the literature.[3][4]

In a study conducted by Shields and al, involving 150 patients, the average age was 5 years with 76% boys, mostly unilateral but without preference for one side . [4]

In our series, patients presented for strabismus, leukocoria or decreased visual acuity which corresponds to international studies.

Patients eye funduscopy matches the literature. This one describes voluminous exudates, of imprecise contours, with a yellowish color scattered with brighter refractive elements in the subretinal space. These exudates surround telangiectasia located at the vascular bifurcations, isolated or grouped in clusters or rosaries. [4]

At the beginning, the localization is equatorial. These exudates then progress towards the macular region giving a macular star aspect. Microaneurysms and tortuous vessels of irregular calibre are also observed. The presence of peripheral preretinal neo-vessels is less frequent. Telangiectasia may be surrounded by a small focus of intraretinal bleeding. More rarely, retrohyaloid hematomas or intravitreal hemorrhages are described.

Concerning additional tests, ultrasound is indicated in the literature mainly to diagnose retinal detachments and to make the difference with a retinoblastoma. It shows the extend of subretinal exudates, and the degree of retinal detachment. It mainly exclude the presence of solid mass lesion and calcification (found in retinoblastoma). [5]

Fluorescein angiography with Retcam allows to observe retinal ischemia with peripheral capillary bed rarefaction. It can guide treatment for children with early Coats' disease. Indirect laser can be administered to the avascular regions and direct laser or cryotherapy can be administered to the telangiectatic vessels.[6]

The main differential diagnosis is retinoblastoma. Clinical and radiological similarities can distort the diagnosis. Orbital MRI is very contributive. It shows for Coats disease, a hyper-intense appearance in T1 and T2 that does not increase after gadolinium injection. Retinoblastoma appears as an hyperintense lesion in T1, hypointense in T2 and increases after gadolinium injection.

Laser photocoagulation is widely used according to the literature. It is a first-line treatment. It targets peripheral vascular abnormalities as well as capillary non-perfusion areas visualized on fluorescein angiography. It can be combined with other treatments to obtain a better result.

The most used wavelength is 532 nm corresponding to a green laser. It is well absorbed by hemoglobin. The cryoapplication followed by treatment by photocoagulation, shows satisfactory results. It is sometimes necessary to have several sessions. Number of sessions are determined based on effectiveness [5]

Anti-VEGF is the subject of many recent articles. The administration of 1.25 mg of Bevacizumab before starting conventional treatments (photocoagulation, cryotherapy) showed positive results on exudates with improvement in post-therapeutic visual acuity as shown by the study conducted by Gold et al [7] as well as that conducted by Lihong Yang et al in 2016 . [6]

According to a study made by Meunier and associates, Ranibizumab would be interesting to use in the treatment of Stage 4 of Coats disease. In fact, according to this study, rubeosis and neovascular glaucoma regressed in all patients within 2 weeks. Injection of Ranibizumab would also have an effect on retinal detachment. [8]

However, bevacizumab injections are not without consequences. They may increase the progression of vitreoretinal fibrosis and create tractional retinal detachments.

Intravitreal corticosteroids reduce the subretinal fluid and exudates. They also have an effect on the size of telangiectasias. It facilitates other treatments . It can be used at the beginning of the therapeutic management. [9] The vitreoretinal surgery can be indicated in stages 3 and 4 with detachments or proliferative vitreoretinopathy. Enucleation is strictly reserved for the non-functional and painful eye. In patients with Coats disease with cataract, the visual prognosis seems to be poor. A cataract surgery allowing a better visibility is to be discussed according to the cases. [10]

Authors declared they have no conflict of interest

REFERENCES :

- [1]. Sigler EJ, Calzada JI. RETINAL ANGIOMATOUS PROLIFERATION WITH CHORIORETINAL ANASTOMOSIS IN CHILDHOOD COATS DISEASE: A Reappraisal of Macular Fibrosis Using Multimodal Imaging. *Retina*. 2015;35(3):537–546.
- [2]. Shields JA, Shields CL, Honavar SG, Demirci H, Cater J. Classification and management of Coats disease: the 2000 Proctor Lecture. *American Journal of Ophthalmology*. 2001;131(5):572–583.
- [3]. Shields JA, Shields CL, Honavar SG, Demirci H. Clinical variations and complications of Coats disease in 150 cases: the 2000 Sanford Gifford Memorial Lecture. *American Journal of Ophthalmology*. 2001;131(5):561–571.
- [4]. Boucher S, Rodier Bonifas C, Mathis T, Janin-Manificat H, Fleury J, Burillon C. Maladie de Leber-Coats : étude rétrospective sur 10 cas. *Journal Français d'Ophthalmologie*. 2016;39(2):133–138.
- [5]. Cebeci Z, Bayraktar Ş, Yılmaz YC, Tuncer S, Kir N. Evaluation of Follow-Up and Treatment Results in Coats' Disease. *tjo*. 2016;46(5):226–231.
- [6]. Yang Q, Wei W, Shi X, Yang L. Successful use of intravitreal ranibizumab injection and combined treatment in the management of Coats' disease. *Acta Ophthalmol*. 2016;94(4):401–406.
- [7]. Gold A, Villegas V, Murray T, Berrocal A. Advanced Coats' disease treated with intravitreal bevacizumab combined with laser vascular ablation. *OPHTH*. 2014;973.
- [8]. Gaillard M-C, Mataftsi A, Balmer A, Houghton S, Munier FL. RANIBIZUMAB IN THE MANAGEMENT OF ADVANCED COATS DISEASE STAGES 3B AND 4: Long-term Outcomes. *Retina*. 2014;34(11):2275–2281.
- [9]. Sallam A. Short-term Safety and Efficacy of Intravitreal Triamcinolone Acetonide for Uveitic Macular Edema in Children. *Arch Ophthalmol*. 2008;126(2):200.
- [10]. Daruich A, Matet A, Munier FL. Cataract development in children with Coats disease: risk factors and outcome. *Journal of American Association for Pediatric Ophthalmology and Strabismus*. 2018;22(1):44–49.

Table I: Different stages of the disease in patients of our series according to Shields Classification

Stage	Findings	Eyes
1	Retinal telangiectasia only	0
2	A :Telangiectasia and extrafoveal exudation	0
	B :Telangiectasia and foveal exudation	3
3	Exsudative subtotal retinal detachment	5
4	Total retinal detachment and glaucoma	6
5	Advanced endstage disease	2

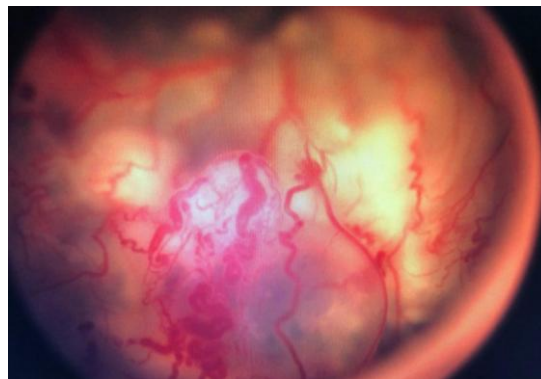


Figure 1: eye fundus showing telangiectasia with sub-retinal exudate

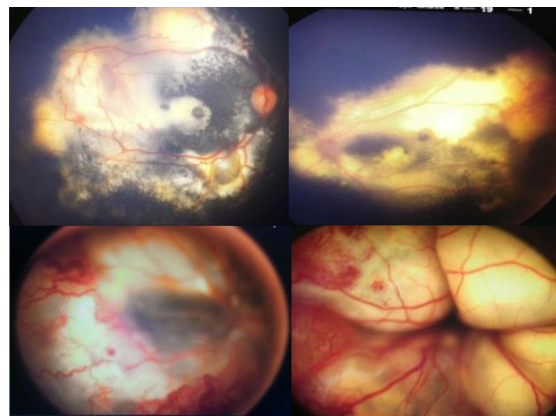


Figure 2: Different stages of Shields classification.

- A: Telangiectasia with diffuse exudates, imprecise contours, and a yellowish characteristic colour (Stage 2B).
- B: Massive retinal exudation with temporal telangiectasia (Stage 2B).
- C: Partial exudative retinal detachment associated with telangiectasia and retinal bleeding (stage 3).
- D: Total retinal detachment (Stage 4)

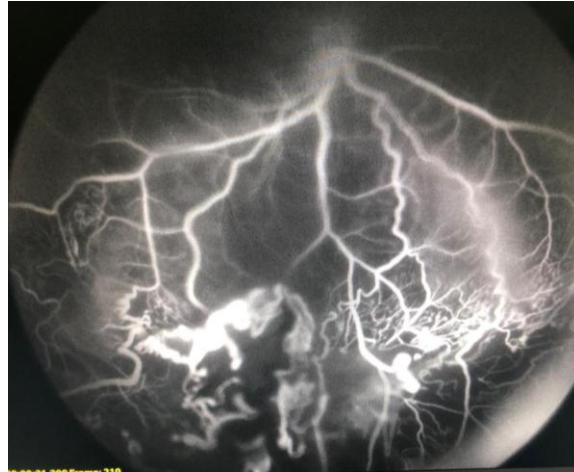


Figure 3: Fluorescein angiography showing fusiform segment dilation, microaneurysms, arterio-venous shunts and areas of late capillary occlusion.

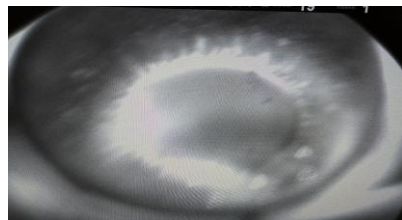


Figure 4: Fluorescein angiography showing rubeosis

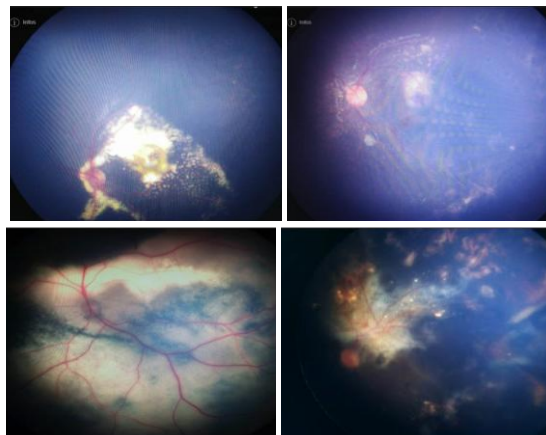


Figure 5: Retcam pictures of the results after treatment with 3 laser photocoagulation sessions (Left: before treatment; Right : after treatment).